

# Xanthogranulomatous Salpingitis is a Rare Case with Clinicopathological Aspects

## Klinikopatolojik Yönleri ile Nadir Bir Olgu Ksantogranülatöz Salpenjit

© Ayşe Nur UĞUR KILINÇ, © Ümmügülüm ESENKAYA

Konya City Hospital, Clinic of Obstetrics and Gynecology, Konya, Turkey

Cite as: Uğur Kılınç AN, Esenkaya Ü. Xanthogranulomatous Salpingitis is a Rare Case with Clinicopathological Aspects. Forbes J Med 2022;3(2):212-214

### ABSTRACT

Xanthogranulomatous inflammation is a rare form of chronic inflammatory that can affect various organs. Xanthogranulomatous salpingitis is a rare entity and to date, a limited number of cases have been reported in the literature. In this report, we present a 39-year-old female patient who presented with pelvic inflammatory disease symptoms in her vaginal culture with *Escherichia coli* growth and was diagnosed with xanthogranulomatous salpingitis by histopathological examination. Although rare, xanthogranulomatous salpingitis should be kept in mind as one of the differential diagnoses of tubo-ovarian masses. When these benign lesions are encountered, all possible efforts should be made to find the factors that cause the etiology and to make the correct diagnosis for complete treatment.

**Keywords:** Xanthogranulomatous inflammation, salpingitis, pelvic inflammatory disease

### ÖZ

Ksantogranülatöz enflamasyon, çeşitli organları etkileyebilen nadir bir kronik enflamasyon şeklidir. Ksantogranülatöz salpenjit nadir görülen bir durumdur ve literatürde bugüne kadar sınırlı sayıda olgu bildirilmiştir. Bu yazıda vajinal kültüründe pelvik enflamatuvar hastalık semptomları ve *Escherichia coli* üremesi ile başvuran, histopatolojik inceleme ile ksantogranülatöz salpenjit tanısı konulan 39 yaşında kadın hasta sunulmaktadır. Nadir de olsa ksantogranülatöz salpenjit tubo-ovaryan kitlelerin ayırıcı tanılarından biri olarak akılda tutulmalıdır. Doğru tanı için uğraşılmalı, tam tedavi için etiyojolojiye sebep olan etkenler araştırılmalıdır.

**Anahtar Kelimeler:** Ksantogranülatöz enflamasyon, salpenjit, pelvik enflamatuvar hastalık

Received/Geliş: 07.12.2021

Accepted/Kabul: 04.01.2022

Corresponding Author/  
Sorumlu Yazar:

Ayşe Nur UĞUR KILINÇ MD,

Konya City Hospital, Clinic of  
Obstetrics and Gynecology, Konya,  
Turkey

Phone: +90 506 238 55 04

✉ aysenurugur@hotmail.com

ORCID: 0000-0002-0439-0101

### INTRODUCTION

Xanthogranulomatous inflammation is a rare form of chronic inflammatory that can affect various organs.

Although it can be seen in many organs, including the gallbladder and kidney, it is rarely seen in the tuba. Rare case reports have been reported in the literature, except for the 13-series analysis of the recently published Chiesa-Vottero.<sup>1-3</sup>

It is characterized by massive infiltration of lipid-laden histiocytes, lymphocytes, plasma cells, and polymorphonuclear leukocytes.<sup>1</sup> Chronic inflammation

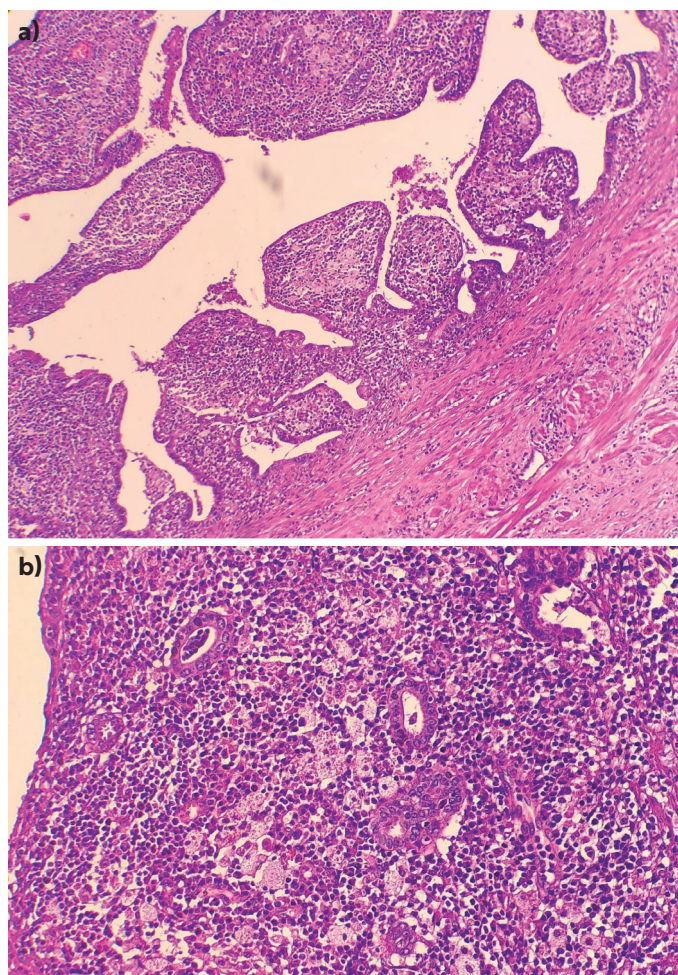
and necrosis release cholesterol and other lipids from dead cells and the phagocytosis of macrophages by the xanthomatous process.<sup>2</sup>

### CASE REPORT

A 39-year-old female patient, who was married to two survivors, was admitted to the hospital with external abdominal pain, pelvic mass, and C-reactive protein (CRP) elevation. The patient had no known chronic disease or surgical history. On physical examination, pain, fullness, and abdominal pain were detected in the suprapubic region and there was no fever. The transvaginal ultrasonography



showed a 7 mm regular endometrium and cystic mass with 8x6 cm septa in the left ovary. In laboratory values; hemogram: 9.8 g/dL, white blood cell: 20.600 CRP: 190 mg/L beta hCG: negative. Magnetic resonance imaging revealed a 6x3 cm-complicated tuba ovarian abscess in the left ovarian region, and cystic formation and diffuse thickening and enhancement of the peritoneal surfaces (peritonitis?). Empirical metronidazole and ceftriaxone treatment was started. When the CRP values did not decrease sufficiently and the pain persisted, the patient who completed her fertility decided to undergo surgical treatment and left salphingoopherectomy + right salpingectomy was performed. Histopathological examination revealed mixed acute and chronic inflammatory infiltrate with foam histiocytes in the right side tubal tissue (Figure 1). Thienam + metronidazole treatment was administered with the suggestion of infectious diseases due to extended



**Figure 1.** a) Xanthogranulomatous inflammation under the tubal plica, foamy histiocytes mixed with lymphocytes, and plasmocytes H&E 40X, b) The xanthogranulomatous inflammation with foamy histiocytes and lymphocytes and plasmocytes H&E 200X

spectrum beta lactamase (ESBL)-positive *Escherichia coli* growth in vaginal culture. The patient's clinical and physical examination findings were normal and he was discharged.

## DISCUSSION

Xanthogranulomatous inflammation is relatively common in the gallbladder and kidney, but is rare in the female genital tract. In the literature, several publications have reported that can be observed in the female genital system located in the tuba ovary and endometrium.<sup>3-5</sup>

Xanthogranulomatous salpingitis is a disease in which various causes play a role, but the pathogenesis is not known. Xanthogranulomatous salpingitis is often associated with widespread endometriosis and IUD use. In some cases, a type of coliform bacteria is probably effective.<sup>6</sup> In accordance with the literature, ESBL+ *Escherichia coli* growth was observed in this study in vaginal culture. In rare cases, contrast agents and endometrial carcinoma have been associated.<sup>3,4,7</sup> It can be seen in the reproductive and postmenopausal periods and the age distribution is variable.<sup>3,7</sup> Patients come with symptoms of pelvic inflammatory disease, such as fever, pelvic pain, and bleeding. The definitive diagnosis is made histopathologically. Although it is a benign disease, it requires treatment for the underlying etiology such as antibiotics and surgery. On histological examination, it was mixed with marked acute and chronic inflammatory infiltrate with foamy histiocytes under the tubal epithelium. In the differential diagnosis of histopathology, the presence of acute and chronic inflammatory infiltrates differentiates from pseudoxanthomatous salpingitis. Also, brown cytoplasmic lipofuscin pigment is seen in the pseudoxanthoma. Another entity that comes to mind in the histopathological differential diagnosis is granulomatous salpingitis. In granulomatous salpingitis, well-developed granulomas should be seen.<sup>3,7</sup> In addition to this histopathological differential diagnosis, radiological findings may mimic ovarian neoplasm and cause misdiagnosis.<sup>2</sup>

Although xanthogranulomatous salpingitis are rare; it should be kept in mind as one of the differential diagnoses of tubo-ovarian masses. When these benign lesions are encountered, all possible efforts should be made to find the factors that cause the etiology and to make the correct diagnosis for complete treatment.

## Ethics

**Informed Consent:** Consent form was filled out by a participant.

**Peer-review:** Externally peer-reviewed.

### Authorship Contributions

Surgical and Medical Practices: A.N.U.K., Ü.E., Concept: A.N.U.K., Design: A.N.U.K., Data Collection or Processing: A.N.U.K., Analysis or Interpretation: A.N.U.K., Ü.E., Literature Search: A.N.U.K., Ü.E., Writing: A.N.U.K.

**Conflict of Interest:** No conflict of interest was declared by the authors.

**Financial Disclosure:** The authors declared that this study received no financial support.

### REFERENCES

1. Zhang XS, Dong HY, Zhang LL, Desouki MM, Zhao C. Xanthogranulomatous inflammation of the female genital tract: report of three cases. *J Cancer*. 2012;3:100-6.
2. Yener N, Ilter E, Midi A. Xanthogranulomatous salpingitis as a rare pathologic aspect of chronic active pelvic inflammatory disease. *Indian J Pathol Microbiol*. 2011;54:141-3.
3. Chiesa-Vottero A. Xanthogranulomatous Salpingitis. *Int J Gynecol Pathol*. 2020;39:468-72.
4. Inoue T, Oda K, Arimoto T, Samejima T, Takazawa Y, Maeda D, et al. Xanthogranulomatous inflammation of the perimetrium with infiltration into the uterine myometrium in a postmenopausal woman: a case report. *BMC Womens Health*. 2014;14:82.
5. Bhatnagar K, Narang V, Garg B, Sood N. Xanthogranulomatous Oophoritis: A Rare Case Report. *Iran J Pathol*. 2018;13:372-6.
6. Juneja SK, Virk SS, Sharma A, Sood N, Sood A. Xanthogranulomatous salpingitis - pathological aspect of chronic pelvic inflammatory disease in a patient with sigmoid diverticulitis. *Int J Reprod Contracept Obstet Gynecol*. 2018;7:3893-5.
7. Crum CP, Laury AR, Hirsch MS, Quick CW, Peters WA. Xanthogranulomatus Salpinigitis High Yield Pathology Gynecologic and Obstetric Pathology. Elseiver Philedelphia; 2016. p. 515-6.