

Ventricular Fibrillation Caused by a Low-Rate Pacemaker

Düşük Hızlı Pacemakerin Neden Olduğu Ventriküler Fibrilasyon Olgusu

İD Hüseyin YILDIZ¹, İD Ayşe SÜLÜ², İD Osman BAŞPINAR²

¹Medicana Konya Hospital, Konya, Türkiye

²Gaziantep University Faculty of Medicine, Department of Pediatric Cardiology, Gaziantep, Türkiye

Cite as: Yıldız H, Sülü A, Başpınar O. Ventricular fibrillation caused by a low-rate pacemaker. Forbes J Med. [Epub Ahead of Print]

ABSTRACT

After undergoing surgery for a perimembranous ventricular septal defect and discrete membrane resection, a 7-year-old patient developed complete atrioventricular block and received an epicardial pacemaker. When the epicardial pacemaker reached end-of-life status, a transvenous pacemaker was implanted. Due to the low basal rate setting of this newly implanted transvenous pacemaker, the patient experienced bradycardia-induced acquired long-QT syndrome (LQTS), subsequently resulting in episodes of ventricular fibrillation. This case report discusses the mechanisms leading to acquired LQTS and fibrillation, and emphasizes the importance of an appropriate basal pacing rate, especially in pediatric patients, to avoid life-threatening arrhythmias.

Keywords: Acquired long QT syndrome, pacemaker, bradycardia, ventricular fibrillation

ÖZ

Perimembranöz ventriküler septal defekt ve diskret membran rezeksiyonu ameliyatı geçiren 7 yaşındaki bir hastada, ameliyat sonrasında tam atriyoventriküler blok gelişmiş ve bu nedenle epikardiyal pacemaker implante edilmiştir. Epikardiyal pacemaker'in ömrünün sonuna gelmesi üzerine, transvenöz bir pacemaker takılmıştır. Ancak yeni implante edilen transvenöz pacemaker'in düşük bazal hız ayarı, hastada bradikardi kaynaklı edinsel uzun QT sendromuna (LQTS) neden olmuş ve bu da ventriküler fibrilasyon atakları ile sonuçlanmıştır. Bu olgu sunumunda, edinsel LQTS ve fibrilasyona yol açan olası mekanizmalar ele alınmakta ve özellikle pediatrik hastalarda uygun bazal pace hızının, yaşamı tehdit edebilecek aritmileri önlemedeki önemi vurgulanmaktadır.

Anahtar Kelimeler: Kazanılmış uzun QT sendromu, pacemaker, bradikardi, ventriküler fibrilasyon

Received/Geliş: 17.02.2025

Accepted/Kabul: 12.06.2025

Epub: 17.07.2027

**Corresponding Author/
Sorumlu Yazar:**

Osman BAŞPINAR, MD,

Gaziantep University Faculty of
Medicine, Department of Pediatric
Cardiology, Gaziantep, Türkiye

✉ osmanbaspinar@hotmail.com

ORCID: 0000-0002-9307-0344

INTRODUCTION

Long QT syndrome (LQTS) is a cardiac repolarization disorder that can be congenital or acquired, potentially leading to life-threatening arrhythmias and sudden cardiac death.¹ The QT interval encompasses both depolarization and repolarization phases; however, prolongation of the repolarization phase is the principal contributor to LQTS. Clinical manifestations range from mild symptoms such as dizziness to fatal events, often precipitated by torsade de pointes (TdP). Moreover, TdP may degenerate into ventricular fibrillation (VF), causing sudden cardiac death.¹

Acquired LQTS is more common than congenital LQTS. Bradyarrhythmias, including those induced by inadequate pacing rates, represent a significant risk factor by prolonging the action potential duration and facilitating early after depolarizations.² In the pediatric population, prompt identification and management of acquired LQTS is crucial given the higher incidence of severe or fatal outcomes compared to adults, even in seemingly low-risk clinical settings.¹



Copyright© 2025 The Author. Published by Galenos Publishing House on behalf of Buca Seyfi Demirsoy Training and Research Hospital. This is an open access article under the Creative Commons AttributionNonCommercial 4.0 International (CC BY-NC 4.0) License.

Copyright© 2025 Yazar. Buca Seyfi Demirsoy Eğitim ve Araştırma Hastanesi adına Galenos Yayınevi tarafından yayımlanmıştır. Creative Commons Atıf-GayriTicari 4.0 Uluslararası (CC BY-NC 4.0) Uluslararası Lisansı ile lisanslanmış, açık erişimli bir makaledir.



CASE REPORT

A 7-year-old, 17 kg male patient developed complete atrioventricular (AV) block following surgery for a perimembranous ventricular septal defect, and discrete membrane resection. An epicardial pacemaker was previously implanted; however, when the device reached its end-of-life, a transvenous pacemaker was implanted. A single chamber pacemaker generator was attached to the lead, the pacemaker's basal rate was set to 50 beats per minute. During the procedure, the patient's intrinsic heart rate was noted to be very low (35-40 bpm) when the pacemaker was temporarily off.

Eighteen hours post-implantation, the patient experienced brief episodes of VF (Figure 1). Between these episodes, the patient's heart rhythm was paced at 50 bpm, and there were no hemodynamic instabilities. A review of the patient's electrocardiograms after implantation revealed a prolonged corrected QT ranging from 507 ms to 547 ms (Figure 2). The patient started taking propranolol. Pacemaker function was verified and found to be effective. However, as VF episodes persisted, the pacemaker's basal rate was increased from 50 bpm to 90 bpm, after which VF episodes ceased, and a stable paced rhythm was maintained.

Because the patient's QT interval remained prolonged (QTc >500 ms), an implantable cardioverter-defibrillator (ICD) with pacemaker capability was deemed necessary. The transvenous pacemaker was removed, and a single chamber ICD was implanted at a more appropriate basal rate, taking the patient's age-related heart rate range into account. During monitored follow-up, no further VF episodes were observed. The ICD functioned without

complications, and the patient's clinical course remained uneventful under regular outpatient follow-up. Informed consent was obtained from patient's parents to publish this very special medical condition.

DISCUSSION

Acquired LQTS occurs more frequently than the congenital form; its exact incidence remains unknown.¹ The most common causes include medications that prolong the QT interval ranging from antiarrhythmic agents (quinidine, procainamide, sotalol, amiodarone) to various non-cardiac drugs (macrolide antibiotics, certain antifungals, some antipsychotics) and electrolyte imbalances (hypokalemia, hypomagnesemia, hypocalcemia).¹⁻³ Other etiologies include any process causing bradycardia, such as advanced AV block, sick sinus syndrome, hypothyroidism, or hypothermia, each of which increases the risk for early after depolarizations and TdP.¹⁻⁴

In this patient, no potential QT-prolonging drugs or significant electrolyte disturbances were identified, and thyroid function tests were normal. Electrocardiograms did not suggest any form of sick sinus syndrome. However, both the patient's intrinsic rhythm (35-40 bpm) and the pacemaker's set basal rate (50 bpm) were markedly bradycardic relative to the normal pediatric range of 65-135 bpm for children aged 6-10 years. This supports the conclusion that the patient developed bradycardia-induced acquired LQTS secondary to the excessively low pacemaker setting.

Pacemakers can shorten QT duration by maintaining a higher heart rate and preventing pauses that predispose early after

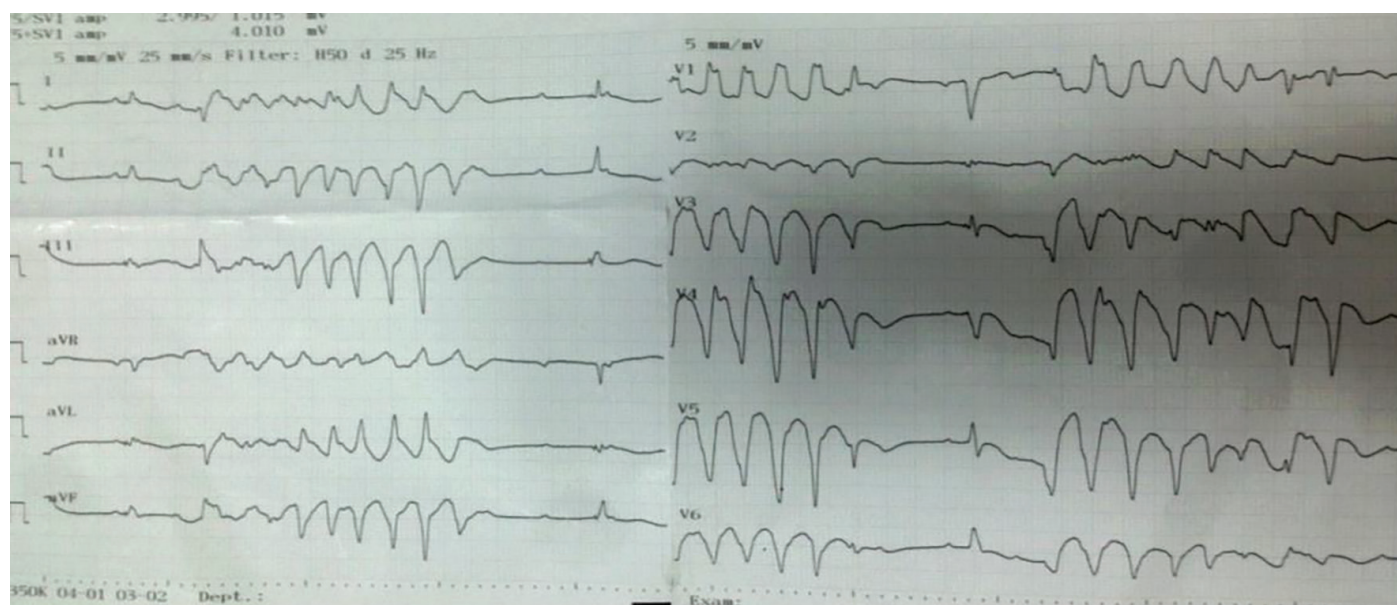


Figure 1. Ventricular fibrillation observed following transvenous pacemaker implantation

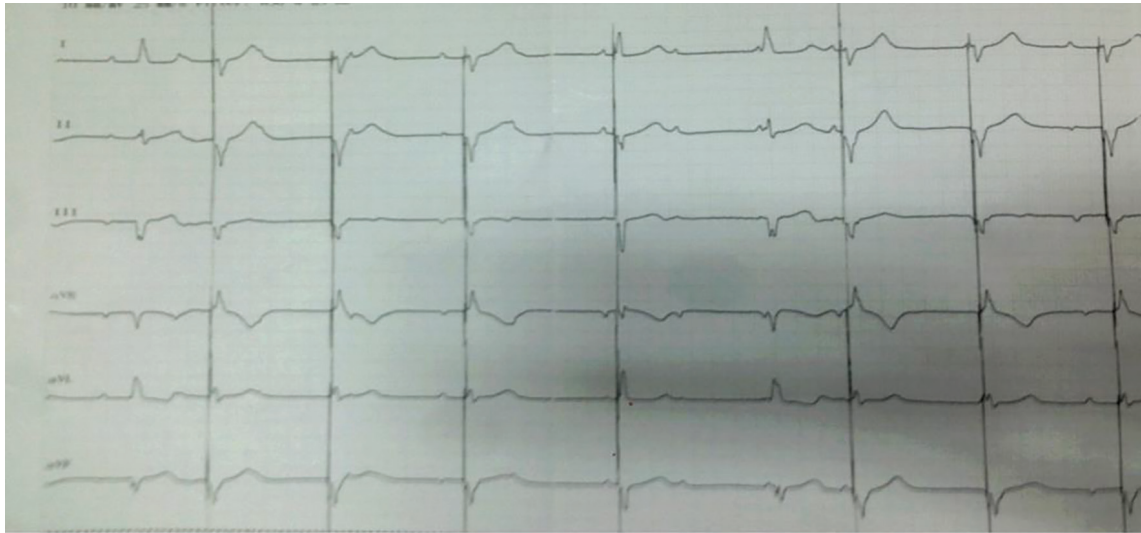


Figure 2. Prolonged QT interval after setting the transvenous pacemaker at a low basal rate

depolarizations. Most pediatric guidelines recommend a basal pacing rate above 80 bpm in patients at risk for LQTS or TdP to ensure more homogeneous repolarization and reduce arrhythmic risk.⁵⁻⁶ Consistent with these recommendations, increasing the pacemaker rate from 50 bpm to 90 bpm in our patient immediately abolished VF episodes, indicating a clear link between bradycardia and the development of LQTS.

Even in adult patients, cases have been reported where a reduction in the pacemaker's basal rate (hysteresis, oversensing, premature ventricular contractions, postventricular atrial refractory period, medications) led to QTc prolongation and TdP. In these cases, TdP was not reported after adjusting the basal rate to >70 beats per minute. It has been suggested that particularly in patients with an increased risk of TdP, such as those using QT-prolonging medications, the basal rate may be set higher.⁵ Similarly our case, Bernstein et al.⁶ reported a case of a pediatric patient with congenital AV block who presented with syncope and was found to have QTc prolongation associated with bradycardia, as well as ventricular tachycardia at a rate of 300 beats per minute, potentially consistent with torsades, during pacemaker interrogation. They emphasized the importance of regular QTc monitoring in the follow-up of these patients after pacemaker implantation.⁶

Children with LQTS, whether congenital or acquired, may present with life-threatening events, such as cardiac arrest, more often than adults. Hence, therapy is recommended even for asymptomatic pediatric patients.³ Beta-blockers reduce the likelihood of arrhythmic events in up to 70% of LQTS patients, but around 30% may still experience breakthrough arrhythmias or sudden death despite optimal medical therapy. For those with a history of cardiac arrest

or recurrent arrhythmic events despite beta-blockade, ICD implantation is the first-line option.³ ICDs provide both anti-bradycardia pacing and arrhythmia termination, significantly improving survival in pediatric patients at high risk for lethal arrhythmias.³⁻⁵

CONCLUSION

To extend pacemaker battery life, clinicians may be tempted to program excessively low basal rates, but this can pose a significant risk factor for acquired LQTS and subsequent malignant arrhythmias in pediatric patients. Maintaining a basal pacing rate appropriate for the patient's age can help prevent the development of bradycardia-induced LQTS and VF episodes. In this case, raising the basal pacemaker rate effectively eliminated VF attacks. Consequently, we recommend carefully considering the minimum basal heart rate for pediatric pacemaker programming, ensuring it remains within a physiologically safe range to minimize arrhythmic complications.

Ethics

Informed Consent: Informed consent was obtained from patient's parents to publish this very special medical condition.

Footnotes

Authorship Contributions

Surgical and Medical Practices: O.B., Concept: O.B., Design: O.B., Data Collection or Processing: H.Y., A.S., Analysis or Interpretation: H.Y., A.S., Literature Search: H.Y., A.S., Writing: H.Y.

Conflict of Interest: No conflict of interest was declared by the authors.

Financial Disclosure: The authors declared that this study received no financial support.

REFERENCES

1. Jackman WM, Friday KJ, Anderson JL, Aliot EM, Clark M, Lazzara R. The long QT syndromes: a critical review, new clinical observations and a unifying hypothesis. *Prog Cardiovasc Dis.* 1988;31:115-72.
2. Ishida S, Takahashi N, Nakagawa M, Fujino T, Saikawa T, Ito M. Relation between QT and RR intervals in patients with bradyarrhythmias. *Br Heart J.* 1995;74:159-62.
3. Zhu W, Bian X, Lv J. From genes to clinical management: a comprehensive review of long QT syndrome pathogenesis and treatment. *Heart Rhythm* 02. 2024;5:573-86.
4. Bhattad PB, Jha A, Wholey R. Bradycardia-induced torsades de pointes in atrioventricular block. *Cureus.* 2023;15:37507.
5. Ashworth SW, Levsky ME, Marley CT, Kang CS. Bradycardia-associated torsade de pointes and the long-QT syndromes: a case report and review of the literature. *Mil Med.* 2005;170:381-6.
6. Bernstein BS, Silver ES, Liberman L. QT prolongation and torsades de pointes in a patient with heart block and a pacemaker. *Cardiol Young.* 2016;26:161-3.